

CLINICAL STUDY: IPJ FUSIONS OF THE LESSER TOES USING THE TRILLIANT SURGICAL TWO-STEP HAMMER TOE IMPLANT, A CANNULATED TITANIUM IMPLANT

Presented by
Nathan Penney, DPM

TWO-STEP HAMMER TOE SYSTEM

Objective

This study was performed to demonstrate the outcome of using the Trilliant Two-Step Hammer Toe implant (a cannulated titanium implant) for fusions of the interphalangeal joints (IPJs) of the lesser toes and benefits over other methods of fixation (Figure 1).

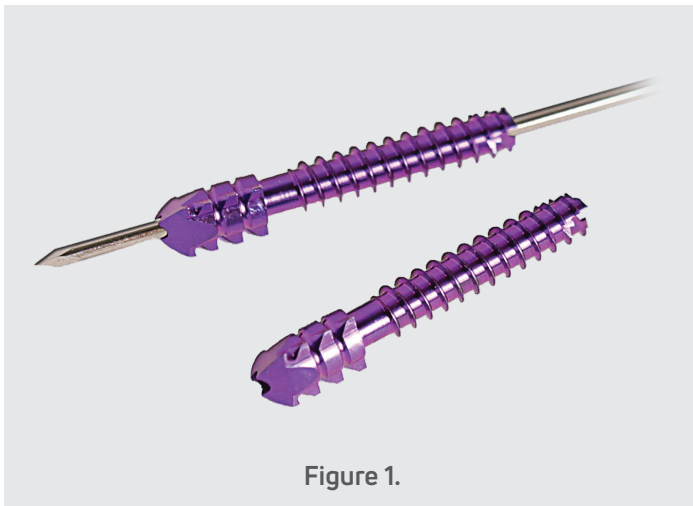


Figure 1.

Materials and Methods

A retrospective chart and x-ray review was performed for patients who underwent fusion of the interphalangeal joint (IPJ) of the lesser toes using Trilliant Surgical's cannulated titanium implant at a single hospital location between July 2013 and January 2015. A total of 20 patient charts were reviewed. There were a total of 22 surgical encounters performed on 25 feet (two patients returned for contralateral surgery and three patients had bilateral surgery performed).

Fifty-one toes, in total, underwent surgical intervention with the Two-Step Hammer Toe implant by a single surgeon. Eight toes had both the distal interphalangeal joint (DIPJ) and proximal interphalangeal joint (PIPJ) corrected by a single implant, all other toes only underwent arthrodesis of the PIPJ. The cannulation guide wire was left in place in the patient, exposed, and covered with a Juergen's pin ball in all 51 toes. Seven toes had the guide wire advanced across the metatarsal phalangeal joint (MPJ) to maintain correction. The test group was made up of 14 females and 6 males. Their ages ranged from 22 years old to 85 years old (Mean 67.2 years, median 71 years). The average follow up length was 76.4 days.

Surgical Technique

The IPJ fusion site is prepared by surgeon preference. This can be done either with a saw to create flat end to end cuts or using the conical reamers (Trilliant Surgical HTR® Hammer Toe Reamers) included in the implant set (Figure 2).



Figure 2.

A Kirschner wire (K-wire) is then inserted through the middle and distal phalanx and out through the distal tuft of the toe until only a small portion of the wire is exposed in the IPJ (Figure 3). The proximal phalanx is then prepared with the drill (Figure 4). The appropriate length implant is then driven into the middle phalanx until flush with the cortex of the bone with one of the spade fins pointed dorsally (Figure 5). The implant is then impacted into the proximal phalanx and the guide wire is advanced to the preferred depth (Figure 6).

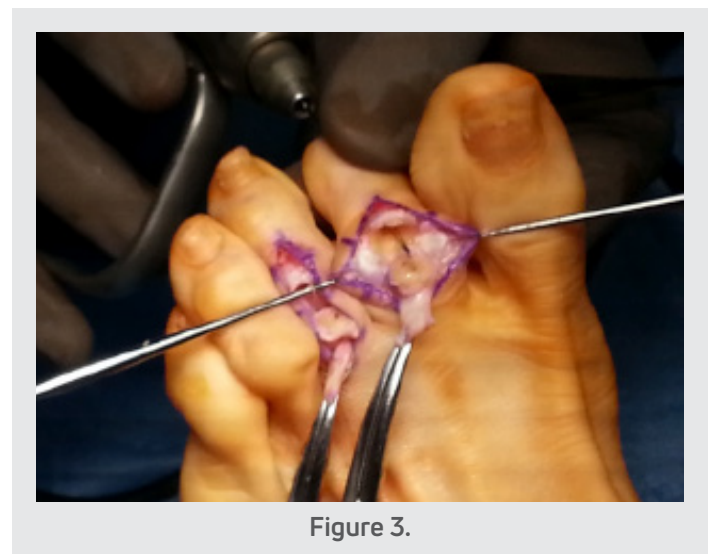

Figure 3.

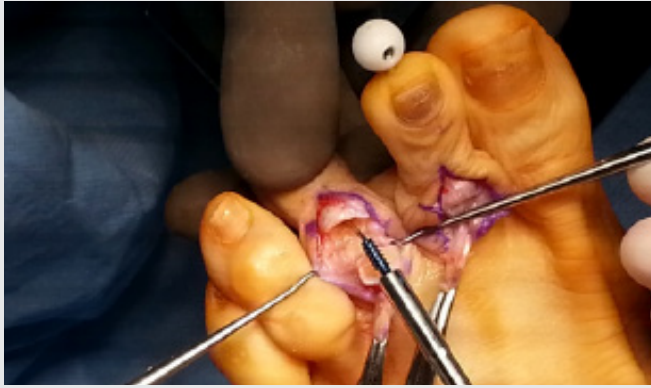

Figure 4.

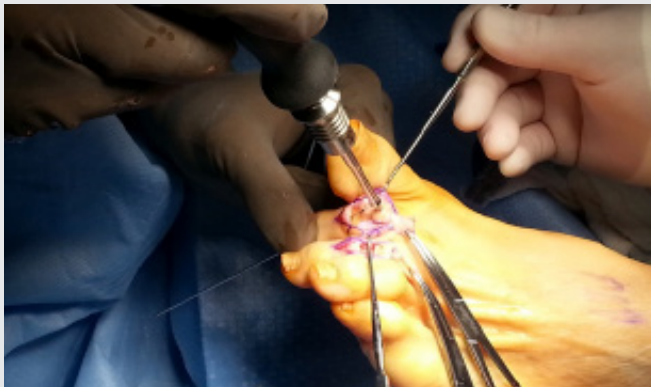


Figure 5.

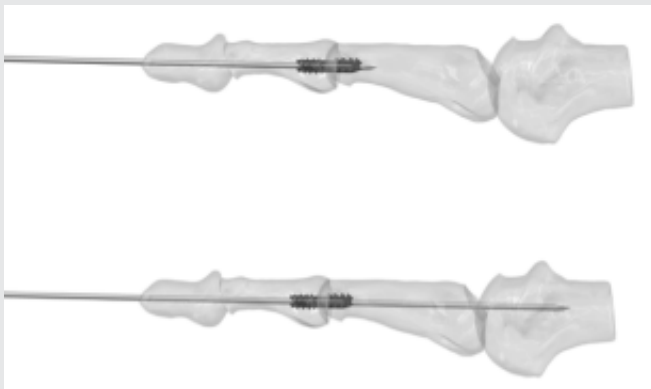

Figure 6.

Slight variation of the technique is necessary if both the PIPJ and DIPJ are to be fused with the implant. First the DIPJ must also be prepared per the surgeons preferred technique. Then, when the K-wire is first inserted, it is only driven to the mid portion of the distal phalanx. Placement of the K-wire is checked with c-arm and the length of the implant is checked with the depth gauge. The middle phalanx is then drilled prior to advancing the K-wire out of the distal tuft of the toe. The preparation of the proximal phalanx and the insertion of the implant are then the same as the technique of the isolated PIPJ fusion.

Results

Forty-four toes achieved satisfactory union and deformity correction at final post op follow up visit as demonstrated by plain film radiographs (Figures 7-11). Four toes had asymptomatic non-unions with satisfactory clinical correction. One toe had a non-union with deformity but did not require surgical revision. Two toes required return to the OR for removal of the implant (one for infection and one for displacement of the implant spade).

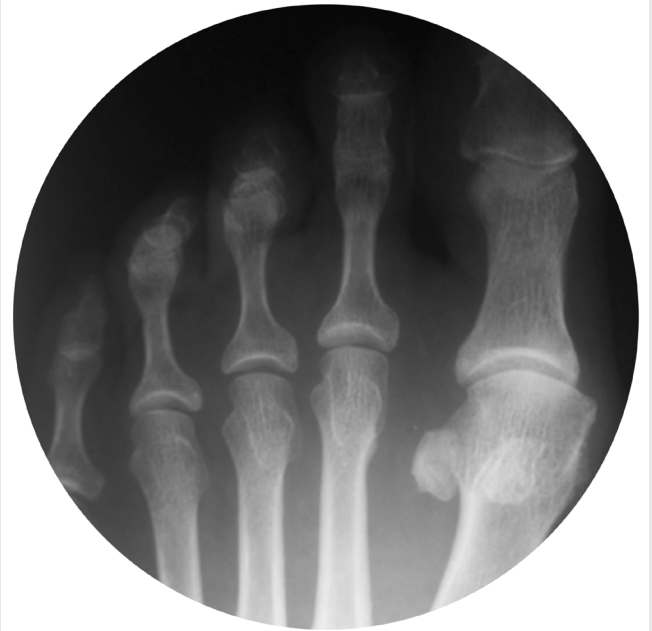

Figure 7.

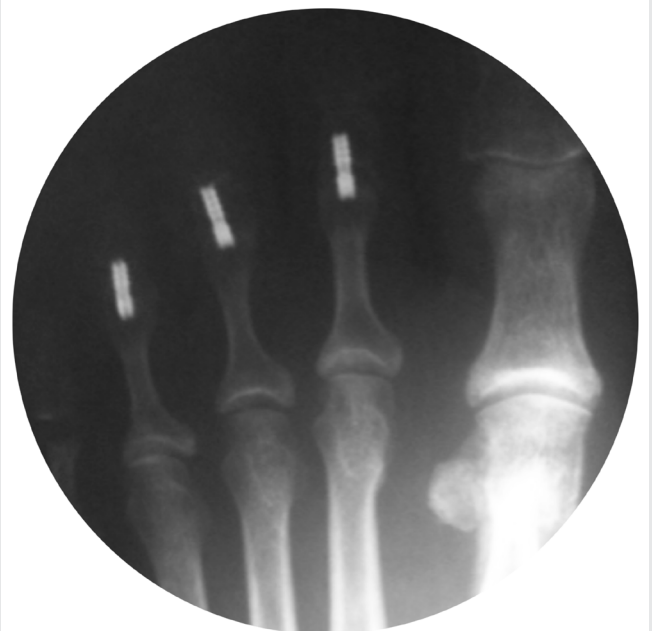

Figure 8.

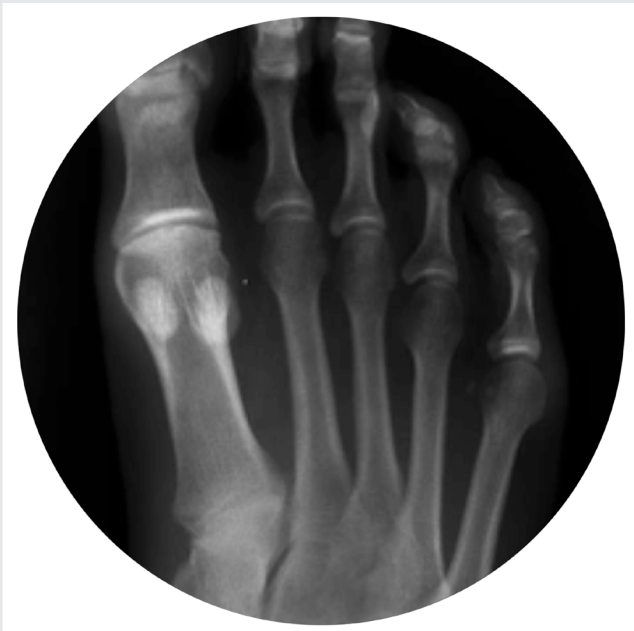

Figure 9.

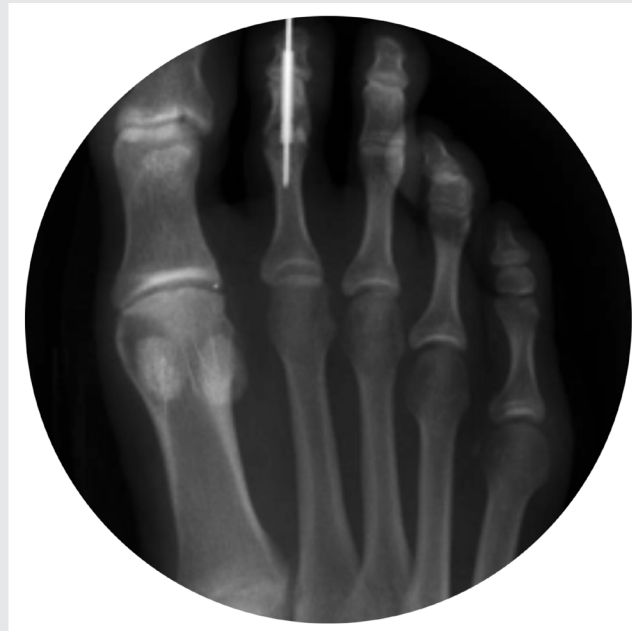

Figure 10.

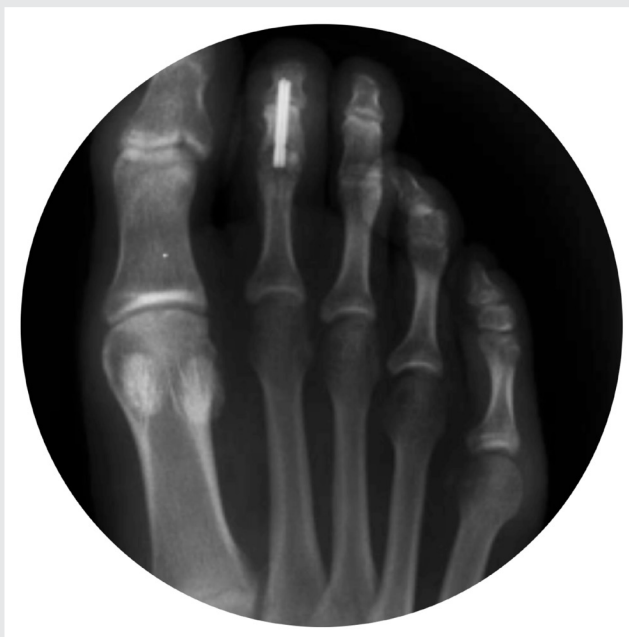

Figure 11.

Conclusion

Hammer toe reconstruction is often achieved through fusion of the IPJ, usually the PIPJ but sometimes the DIPJ or both. Historically, fixation of the fusion site has been through K-wires often left exposed from the distal tip of the toe. The K-wire is then usually removed in the office per surgeon preference anytime between 2 and 6 weeks. Since osseous union usually takes at least 6 weeks to occur, the K-wire is therefore removed prior to union being achieved leaving no fixation of the fusion site. To combat this problem over the last several years, many intermedullary implants have been

developed that maintain stability of the fusion site past 2 to 6 weeks post op. However, studies of these new implants have demonstrated some limitations: inability to correct and stabilize both the PIPJ and DIPJ (or the need for multiple implants to achieve this), inability to maintain temporary correction of either the MPJ or DIPJ while soft tissue is initially healing, displacement of the implant spade components due to the small surgical field, breakage of the implants, lack of implant sizing options to handle varying anatomy, and the need for complex surgical intervention if removal is necessary.

References

1. Moon JL, Kihm CA, Perez DA, Dowling LB, Alder DC. Digital arthrodesis: current fixation techniques. *Clin Podiatr Med Surg* 2011;28:769-83.
2. Ellington JK. Hammertoes and clawtoes: proximal interphalangeal joint correction. *Foot Ankle Clin N Am* 2011;16:547-58.
3. Camasta CA, Cass AD. Buried Kirschner-wire fixation for hammertoe arthrodesis. In: Miller SJ, editor. *Reconstructive surgery of the foot and leg. Update 2008. Tucker (GA): Podiatry Institute; 2008. p. 5-8.*
4. Lamm B, Ribeiro C, Valhovic T, et al. Lesser proximal interphalangeal joint arthrodesis: a retrospective analysis of the peg-in-hole and end-to-end procedures. *J Am Podiatr Med Assoc* 2001;91:331-6.
5. Konkel K, Menger A, Retzlaff S. Hammer toe correction using an absorbable intramedullary pin. *Foot Ankle Int* 2007;28:916-20.
6. Caterini R, Farsetti P, Tarantino U, et al. Arthrodesis of the toe joints with an intramedullary cannulated screw for correction of hammertoe deformity. *Foot Ankle Int* 2004;25:256-61.
7. Fernandez CS, Wagner E, Ortiz C. Lesser toes proximal interphalangeal joint fusion in rigid claw toes. *Foot Ankle Clin N Am* 2012;17:473-80.
8. Vitek M. A new technique for hammertoe arthrodesis. *Foot Ankle Surg* 2009;15:54-6.
9. Angirasa AK, Barrett MJ, Silvester D. SmartToe Implant compared with Kirschner wire fixation for hammer digit corrective surgery: a review of 28 patients. *J Foot Ankle Surg* 2012;51:711-3.
10. Witt BL and Hyer CF. Treatment of hammertoe deformity using a one-piece intramedullary device: A case series. *Foot Ankle Surg* 2012;51:450-6.
11. Vanore J. The case against the use of new technologies for hammertoe repair. *The Podiatry Institute Update* 2013;12:61-74.



T 800.495.2919 F 877.778.3864
727 North Shepherd Drive, Suite 100 | Houston, TX 77007 | U.S.A.
djoglobal.com

Copyright © 2021 by DJO, LLC
900-30-006 Rev. C

NOTE: The views and opinions expressed in this white paper are those of the author.

DJO, LLC is a manufacturer of orthopedic implants and does not practice medicine. Only an orthopedic, or foot and ankle surgeon can determine what treatment is appropriate. The contents of this document do not constitute medical, legal, or any other type of professional advice. This material is intended for the sole use and benefit of the DJO, LLC sales force and physicians. It is not to be redistributed, duplicated, or disclosed without the express written consent of DJO, LLC. For more information on risks, warnings, and possible adverse side effects refer to the Instructions for Use provided with the device.